

Received: 2020-02-19
Accepted: 2020-07-08
Published: 2021-01-31

WIRELESS PERIPHERAL NERVE STIMULATION FOR THE TREATMENT OF CHRONIC SHOULDER PAIN

Brian K. Rich, MD¹
Alaa Abd-Elseyed, MD
Niek Vanquathem, BA

Background: Shoulder pain is a common condition, often refractory to treatment. Peripheral nerve stimulation (PNS) of the suprascapular nerve (SSN) can be efficacious in providing relief of shoulder pain while improving pain-related quality of life (QOL). The objective of this case report is to demonstrate the effectiveness of a minimally invasive wireless PNS in the treatment of chronic shoulder pain.

Case Report: This 94-year old man presented with severe shoulder pain. He suffered from poliomyelitis as a child affecting his left leg, forcing him to use crutches to be ambulatory. He developed progressive right shoulder pain and was subsequently diagnosed with right glenohumeral osteoarthritis. The patient was treated semiannually for 4 years with corticosteroids injections and pain medication with minimal relief (7 out of 10 on the Visual Analog Scale [VAS]). A suprascapular block with lidocaine 2% resulted in significant pain reduction (1 out of 10 on the VAS). As a result, the patient opted for wireless PNS of the SSN via a minimally invasive procedure. Two weeks post implant, the patient reported no postoperative pain, and his chronic pain was rated 0 out of 10 even during movement. Reports of reduced pain were sustained throughout the 6 months of observation with subsequent improvements in QOL and functionality.

Conclusion: Wireless neurostimulation of the SSN can be a very effective therapy option for the treatment of refractory, chronic shoulder pain as a result of glenohumeral osteoarthritis.

Key words: Endoscopic spine surgery, lumbar radiculopathy, minimally invasive spine, SI joint fusion

BACKGROUND

The suprascapular nerve (SSN) originates from the upper trunk of the brachial plexus (with some anatomic variability among different individuals), branching from the ventral rami of either C5 and C6 (76%); C4, C5, and C6 (18%); or C5 nerve roots (6%) (1). The SSN can be injured by compression of surrounding structures, anatomical abnormalities, and fractures of adjacent bones (2,3). Management of suprascapular neuropathy typically includes nonpharmacological, pharmacologi-

cal, and interventional pain procedures such as corticosteroid injections and neurolysis. Similar to any other chronic pain condition, shoulder pain can be refractory to these types of treatment.

The next steps in the treatment paradigm are more invasive treatment options, such as spinal cord stimulation (SCS) or peripheral nerve stimulation (PNS). SCS targets the myelinated fibers of the dorsal column while PNS includes placement of electrodes directly at

From: ¹ Accelerated Interventional Orthopedics, Lawton, OK; ² Wisconsin School of Medicine and Public Health, Madison, WI; ³ Stimwave Technologies, Inc., Pompano Beach, FL

Corresponding Author: Niek Vanquathem, BA, E-mail: niekv@stimwavefreedom.com

Disclaimer: There was no external funding in the preparation of this manuscript.

Conflict of interest: Dr. Alaa Abd-Elseyed is a consultant for Stimwave. Niek Vanquathem is an employee of Stimwave.

the inflicted peripheral nerve targets, stimulating the cutaneous afferents of the nerve after they have left the spinal cord (4-6).

Implanted power generator (IPG)-based SCS systems have been widely used off-label throughout the industry to treat peripheral nerve pain. Complications have been known to arise due to the limitations inherent to conventional wired SCS devices, which do not lend themselves to PNS placement due to the extensive tunneling often required between the electrode arrays and the IPG (7). Such complications may include electrode displacement, infection (due to the large areas of tunneling and dissection), and device fracture and battery-related issues, including battery malposition and pocket pain (8-10). Further, none of these devices are rated for magnetic resonance imaging (MRI) scans of the implanted area when utilized at PNS nerve targets.

We report a case using a novel device, devoid of electrode array extensions or IPG, specifically designed to mitigate complications related to the bulk of conventional wired devices by utilizing just an electrode array and a separate receiver element, for a total volume just 5% of the volume of battery devices.

CASE

Preintervention: The patient is a 94-year old widower who suffered from poliomyelitis as a child that affected his left leg and his ability to walk. He lives alone and depends on the use of crutches to ambulate and manage activities of daily living (ADLs). He complained of progressive pain in the right shoulder and deteriorating

mobility. He could not lift his right arm above his head without significant pain. He was diagnosed with right glenohumeral osteoarthritis but was not considered an appropriate candidate for surgery because of his age and medical history. Treatment with glenohumeral shoulder corticosteroids injections and medical treatment (Table 1) over 4 years was found to be ineffective.

When he presented to our Accelerated Interventional Orthopedics facility, the right shoulder examination documented limited mobility (Table 2). The patient’s pain during movement was reported as 7 out of 10 on the Visual Analog Scale (VAS), and the patient complained that the pain was seriously compromising his ability to self-care.

Intervention: A suprascapular injection of 5 mL of lidocaine 2% was given in the suprascapular notch under ultrasound guidance. The patient tolerated the procedure well. Immediately after the injection, an exam of the right shoulder yielded results indicating marked improvements in range of motion (Table 3 and Fig. 1), as well as a reduction in pain under movement from 7 out of 10 to 1 out of 10. The effects of the suprascapular block provided pain relief for 2 days.

Two weeks after the suprascapular block, the patient continued to report reduced pain as measured by the VAS (2 out of 10 with movement) and was better able to manage ADLs. Long-term options included radio-frequency ablation or PNS of the SSN with a minimally invasive procedure. The patient opted for the latter.

DEVICE DESCRIPTION

An 8-contact wireless stimulator with an embedded microprocessor (K171366, StimQ PNS System, Stimwave Technologies Incorporated, Pompano Beach, FL)

Table 1. Medications and doses.

Medication	Daily Dose
Methylprednisolone 4-mg tablet	one oral tablet as directed
Tramadol 50-mg tablet	one oral tablet every 6 hours as needed (PRN)
Etodolac 400-mg tablet	one oral tablet twice a day
Clopidogrel bisulfate 75-mg tablet	one oral tablet
Amlodine/atorvastatin 10-mg to 20-mg tablet	one oral tablet
Omeprazole 20-mg tablet, delayed release	one oral tablet
Solifenacin succinate 10-mg tablet	one oral tablet
Propranolol 60-mg capsule, extended release	one oral capsule

Table 2. Range of motion at initial evaluation.

Range of Motion	Results
Abduction	Restricted (45 degrees)
Adduction	Restricted (45 degrees)
Flexion	Restricted
Extension	Restricted
Internal rotation	Restricted (25 degrees)
External rotation	Restricted (25 degrees)
Muscle testing	Graded at 5/5
Special tests	
• Anterior instability and impingement	Apprehension: positive Relocation: positive
• Inferior laxity	Sulcus: positive
• Voluntary dislocation	negative

Table 3. Range of motion after injection.

Range of Motion	Results
Abduction	90 degrees without pain
Adduction	75 degrees without pain
Flexion	Improved with less pain
Extension	Improved with less pain

was implanted percutaneously under fluoroscopic guidance using a Touhy needle, with the electrodes targeted at the affected SSN. A small, external, rechargeable wireless pulse generator (WPG) with an attached transmitting antenna worn by the patient over a single layer of clothing provided the stimulation parameters and energy via radiofrequency coupling to the receiver, which then relays wireless power to the stimulator electrodes.

PROCEDURE

Trial: The trial implant procedure was done in the prone position with local anesthesia under light sedation. The left border of the scapula was identified by palpation and fluoroscopy, and the track for the trial electrode array was copiously infused with a solution of 5 mL of 0.5% bupivacaine and 5 mL of 2% lidocaine. An 8-cm Tuohy needle was advanced over the medial border of the scapula along the SSN under fluoroscopic guidance (Fig. 2). Once the device was placed, the introducer was removed, and the tubing was fixated to the skin with Tegaderm (3M, Saint Paul, MN) The patient tolerated the procedure well and there were no complications. The trialed programming settings were 1.5 kHz, 32 μs, and 3.5 mA. The patient reported a pain reduction of 100% from the 7-day trial and opted for a permanent implant. The temporary trial device was removed 7 days post implant.

Permanent Implant: The permanent implant was conducted 3 weeks after the trial procedure completion, using local anesthesia and light sedation. After local anesthetic infiltration, a 4-contact StimQ stimulator (Stimwave Technologies Incorporated, Pompano Beach, FL) with built-in fixation tines was placed through the Tuohy introducer to the targeted nerves where the trial device had been and the position was verified

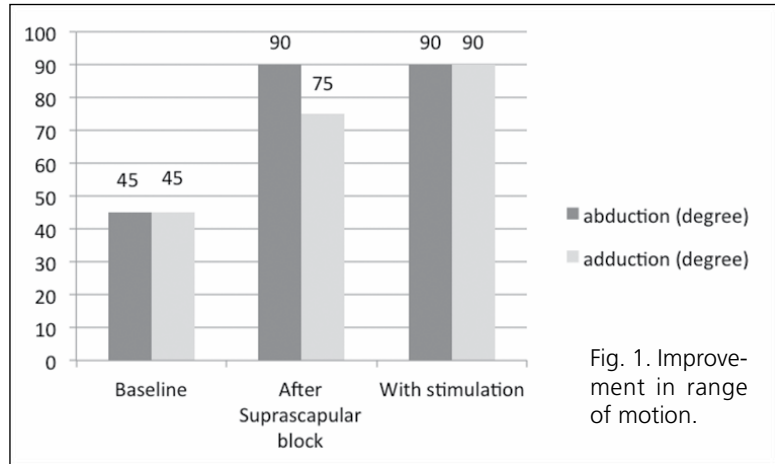


Fig. 1. Improvement in range of motion.

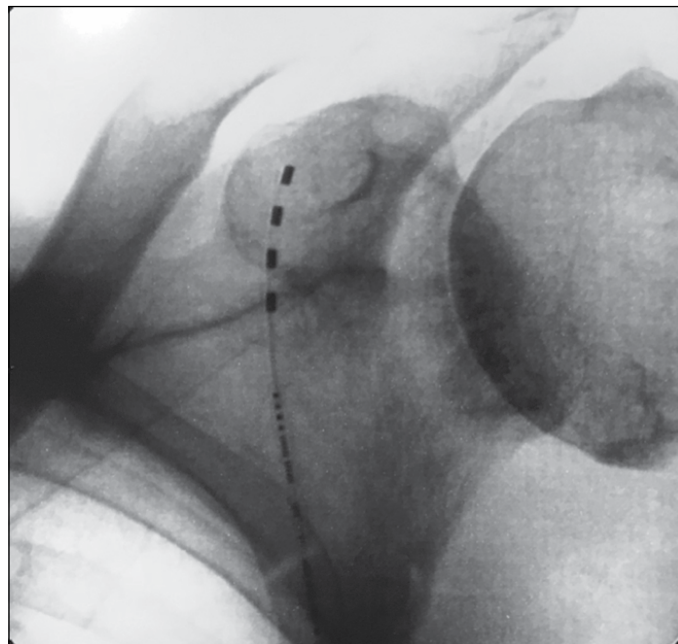


Fig. 2. Anterior-posterior view of device placement.

with fluoroscopy. After the electrode placement and Tuohy needle removal, the placement was verified with renewed testing at settings similar to those found effective during the trial period. A receiver was unpackaged and threaded into the inner lumen of the extruded stimulator body. A receiver pocket approximately 2 cm long was made approximately 12 cm distal from the skin entry point at the lateral latissimus, and the Tuohy needle was utilized to tunnel the receiver the full length of the track to the secondary subcutaneous receiver pocket. The distal portion of the receiver was coiled, sutured to itself to eliminate any sharp ends, and

then sutured to the fascia. Multilayer wound closure was made after copious irrigation and hemostasis. Steri-Strips (3M, Saint Paul, MN) were applied and Tegaderm (3M, Saint Paul, MN) was placed over the incisions. The patient tolerated the procedure well and there were no complications.

RESULTS

The patient was fully recovered and had little to no postoperative pain 2 weeks post-implant. He graded his shoulder pain under movement at 0 out of 10 compared to baseline. The patient stated that 10 hours of stimulation per day was sufficient to maintain that level of relief.

Pain relief was sustained at 6 months, and the patient indicated considerable improvement in QOL, as measured by the Disability of the Arm, Shoulder and Arm Score (8.33 postoperative vs 75 preoperative), Shoulder Pain and Disability Index Pain Scale (12% postoperative), and Disability Scale (10% postoperative). The patient also reported improved mobility in his shoulder (Table 4, Fig. 1) and was more ambulatory since he was able to use his crutch again.

Table 4. Range of motion with wireless stimulation.

Range of Motion	Results
Abduction	90 degrees without pain
Adduction	90 degrees without pain
Flexion	90 degrees without pain
Extension	70 degrees without pain
Internal rotation	Restricted (30 degrees)
External rotation	60 degrees without pain
Muscle testing	Graded at 5/5
Special tests <ul style="list-style-type: none"> • Anterior instability and impingement • Inferior laxity • Voluntary dislocation 	Apprehension: negative Relocation: negative Sulcus: positive negative

DISCUSSION

Suprascapular neuropathic pain can originate from a wide variety of sources and presents with severe, refractory pain as a consequence. The use of wireless PNS of the SSN has had limited reporting in the literature and experience is very limited (11). PNS has historically been used for various etiologies with promising efficacy (12).

This was a unique indication for the use of wireless PNS. The anatomical conditions of the area are such that the implant of a conventional system with an IPG would have been very difficult. Off-label use of SCS components is common and often leads to technical shortcomings (8-10). Reasons for failed PNS include complications such as migration, fracture, malpositioning, and scar tissue along the entire track created by tunneling lead extensions. Complications due to the bulk of these devices include infections and IPG pocket pain (10). With a wireless system, this type of bulk is avoided, and the implantation elements consist of an electrode array and a separate receiver the size of a wire, allowing for device placement in previously untreatable nerve targets and inaccessible areas.

With the overall simplicity of the system and cosmetic advantages, the above-described technology offers an inviting treatment option for similar pathologies that patients will tolerate and utilize widely where they previously would not have considered placement of an active implantable battery unit.

CONCLUSION

Wireless PNS was a successful option for an elderly patient suffering from debilitating right shoulder pain due to glenohumeral osteoarthritis.

Wireless PNS stimulators allow for access to difficult sites, and it is technically less risky for a clinician to place these units and ensure fixation, since joints do not have to be crossed while tunneling to a larger-volume IPG pocket under general anesthesia.

REFERENCES

1. Shin C, Lee SE, Yu KH, Chae HK, Lee KS. Spinal root origins and innervations of the suprascapular nerve. *Surg Radiol Anat* 2010; 32:235-238.
2. Zehetgruber H, Noske H, Lang T, Wurnig C. Suprascapular nerve entrapment. A meta-analysis. *Int Orthop* 2002; 26:339-343.
3. Lee BC, Yegappan M, Thiagarajan P. Suprascapular nerve neuropathy secondary to spinoglenoid notch ganglion cyst: Case reports and review of literature. *Ann Acad Med Singapore* 2007; 36:1032-1035.
4. Tamimi MA, Davids HR, Langston MM, et al. Successful treatment of chronic neuropathic pain with subcutaneous peripheral nerve stimulation: Four case reports. *Neuromodulation* 2009; 12:210-214.
5. Goroszeniuk T, Kothari S, Hamann W. Subcutaneous neuromodulating implant targeted at the site of pain. *Reg Anesth Pain Med* 2006; 31:168-171.
6. Barolat G. Subcutaneous peripheral nerve field stimulation for intractable pain. In: Krames E, Peckham PH, Rezai A (eds). *Neuromodulation*. Elsevier, San Diego, CA, 2009, 1017-1020.
7. Slavin KV. Technical aspects of peripheral nerve stimulation: Hardware and complications. In: Slavin KV (ed). *Peripheral Nerve Stimulation*. *Prog Neurol Surg* 2011; 24:189-202.
8. Kim D, Vakharya R, Kroll HR, et al. Rates of lead migration and stimulation loss in spinal cord stimulation: A retrospective comparison of laminotomy versus percutaneous implantation. *Pain Physician* 2011; 14:513-524.
9. Holsheimer J, Khan YN, Raza SS, et al. Effects of electrode positioning on perception threshold and paresthesia coverage in spinal cord stimulation. *Neuromodulation* 2007; 10:34-41.
10. Eldabe S, Buchser E, Duarte R. Complications of spinal cord stimulation and peripheral nerve stimulation techniques: A review of the literature. *Pain Med* 2016; 17:325-336.
11. Elahi F, Reddy CG. Neuromodulation of the suprascapular nerve. *Pain Physician* 2014; 17:E769-E773.
12. Ilfeld BM, Finneran JJ 4th, Gabriel RA, Said ET, et al. Ultrasound-guided percutaneous peripheral nerve stimulation: Neuromodulation of the suprascapular nerve and brachial plexus for postoperative analgesia following ambulatory rotator cuff repair. A proof-of-concept study. *Reg Anesth Pain Med* 2019; 44:310-318.

