

TAKOTSUBO (STRESS-INDUCED) CARDIOMYOPATHY AFTER RADIOFREQUENCY ABLATION FOR CHRONIC NECK PAIN

Scott A. Blaine, DO, and Keth M. Pride, MD

Background: Radiofrequency ablation (RFA) is a common procedure performed in the management of chronic pain syndromes. Although typically well tolerated, adverse events can be individual and unique to patient comorbidities.

Case Report: We present a case of a 65-year-old woman who developed Takotsubo (stress-induced) cardiomyopathy after undergoing an RFA for chronic neck pain. She presented with chest pain shortly after RFA and was found to have elevated troponin-I, newly reduced left ventricular ejection fraction (25%) with apical akinesis, and no evidence of obstructive coronary artery disease on angiography. She was admitted to the hospital for a short stay and did well. Transthoracic echocardiogram done at follow-up 3 weeks later showed resolution of the wall motion abnormalities and return of left ventricular function.

Conclusion: Although this patient was fortunate to not suffer from a life-threatening outcome, many patients are not so lucky. Recurrence of Takotsubo cardiomyopathy has been shown to result from both similar and novel triggers, which has profound implications for future pain management in this patient.

Key words: Radiofrequency ablation, stress-induced cardiomyopathy, Takotsubo cardiomyopathy

BACKGROUND

Radiofrequency ablation (RFA) is a common procedure performed in the management of chronic pain syndromes. Target nerves are ablated using heat generated from a radiofrequency current, effectively denervating the area. The most common complications that can occur secondary to RFA include pain at the site of entry, paresthesias, or neuritis (1). Much like any procedure, however, complications can be individual and unique to patient comorbidities more so than the procedure itself. We present a case of a woman who experienced Takotsubo (stress-induced) cardiomyopathy following a RFA to treat her chronic neck pain.

CASE

A 65-year-old woman with a past medical history

of hypertension and generalized anxiety disorder underwent RFA of the left third occipital nerve and left C3/4 medial branches to address chronic neck pain. The procedure itself went well; however, in the postoperative area the patient began to experience squeezing chest pressure. She described the pressure as radiating through to her back, but it did not radiate to the jaw or arm and was not associated with diaphoresis or nausea. She was referred to the emergency department for further evaluation.

On arrival her vitals were normal but her pain was still present at a 7 out of 10. She was given one sublingual 0.4-mg nitroglycerin tablet with some relief. On electrocardiogram (ECG) she was in normal sinus rhythm and there were no signs of ischemia. However, on laboratory analysis her troponin-I, drawn approximately 4

From: Department of Anesthesiology, University of Wisconsin, Madison, WI

Corresponding Author: Scott Blaine, DO, E-mail: sblaine@uwhealth.org

Disclaimer: There was no external funding in the preparation of this manuscript.

Conflict of interest: Each author certifies that he or she, or a member of his or her immediate family, has no commercial association (i.e., consultancies, stock ownership, equity interest, patent/licensing arrangements, etc.) that might pose a conflict of interest in connection with the submitted manuscript.

Accepted: 2020-10-16, Published: 2021-05-31

hours after the RFA began, was elevated to 0.29 ng/mL (reference < 0.04). Repeat ECG one hour after the initial ECG showed a pattern of evolving ischemia with T-wave inversions in the lateral precordial leads but no ST-segment changes. Repeat troponin-I 2 hours after the first draw was 0.85 ng/mL. She was admitted to the cardiology service for an ischemic evaluation.

She was taken for coronary angiography, which revealed patent epicardial arteries with no evidence of obstructive coronary artery disease or arterial spasm. Transthoracic echocardiogram (TTE) demonstrated a systolic ejection fraction of 25% (normal > 55%) with akinesis extending from the apex midway up the walls of the left ventricle (Fig. 1). The base of the heart and the right ventricle were normal in appearance and function. Collectively, the imaging findings and her clinical presentation were most consistent with a diagnosis of Takotsubo (stress-induced) cardiomyopathy.

DISCUSSION

Takotsubo (stress-induced) cardiomyopathy is an uncommon but increasingly recognized syndrome. It was first described in the 1990s by its characteristic ballooning and akinesis of the cardiac apex, such that the left ventricle appeared like a pot that Japanese fishermen use to catch an octopus, a takotsubo (2). The classical presentation for this syndrome is an elderly woman who presents with symptoms of acute coronary syndrome (ACS) after extreme emotional or physical stress. However, unlike ACS, the echocardiographic findings in Takotsubo extend beyond a discrete coronary artery distribution. In an acute infarction involving the right coronary artery, for example, one would expect to find wall motion abnormalities involving the inferior wall of

the right ventricle. In Takotsubo, the entire apex of the left ventricle is akinetic, which is a region of the heart that has redundant blood supply.

The pathogenesis of this cardiomyopathy likely involves intense sympathetic activation, diffuse microvascular spasm, and direct catecholamine toxicity (3). In 2015, Templin et al (4) published a retrospective case-control study using data from the International Takotsubo Registry. This database includes 1750 patients diagnosed with Takotsubo cardiomyopathy across 27 countries. Ninety percent of patients in this registry were women and the mean age was 66 years, congruent with the classically described presentation. Interestingly, these patients were much more likely than their age- and sex-matched counterparts who presented with ACS to have a history of neurologic or psychologic diagnoses (55.8% vs 25.7%), implicating a brain-heart axis in the pathophysiology of the syndrome; 42.3% of patients had a history of a psychological diagnosis (e.g., anxiety, depression, or severe stress disorder) and 27% had a history of a neurologic disorder (e.g., seizures, intracranial bleeding, stroke, or a headache disorder). Germane to our case, many of these comorbidities are also common in patients who suffer from chronic pain syndromes.

Of those patients with identifiable preceding triggers, 36% were physical in nature. Examples of these triggers include acute respiratory failure, postsurgical/fracture, central nervous system condition, infection, and malignancy. On cursory search of the literature, we were able to find several case reports of patients experiencing cardiomyopathy following RFA procedures. One patient developed monomorphic ventricular tachycardia and was found to have apical akinesis within 5 minutes of starting a RFA of hepatocellular carcinoma (5). Another case report

described a patient who became hypotensive and was found to have apical akinesis 30 minutes after undergoing RFA of the right ventricular outflow tract (to treat an arrhythmia) (6). Interestingly, the development of symptoms in that

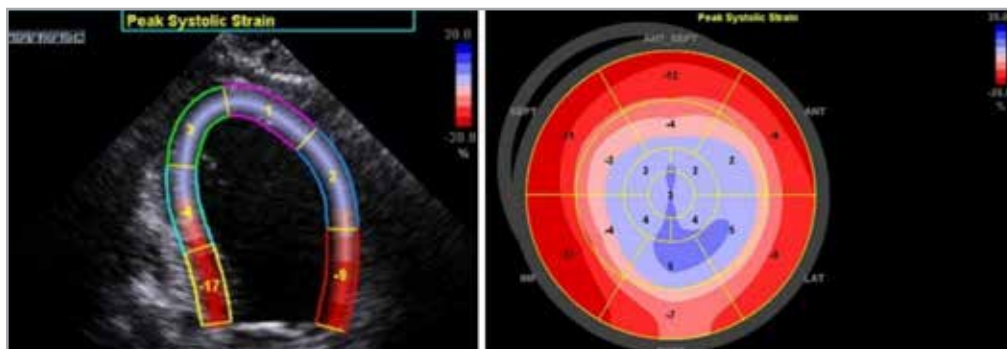


Fig. 1. Computer-generated strain values superimposed over apical view on transthoracic echocardiogram (left), demonstrating apical akinesis (lower strain values in blue) with preserved movement of the rest of the ventricle. Computerized rendition of parasternal short axis view with strain patterns again demonstrating apical akinesis (right).

patient was slightly delayed in a manner that is similar to the patient we present in this report. Intense sympathetic activation as a result of RFA seems to at least provide biologic plausibility as to how these 2 might be linked. In the case of our patient, her troponin was elevated above the normal limit when it was checked approximately 4 hours after the RFA began. This is consistent with the well-described enzyme kinetics of troponin-I, where serum levels become detectable within a few hours of myocyte injury (7).

Although the systolic dysfunction of this syndrome is transient (most returning to normal at 60-day follow-up), serious in-hospital adverse events occur at similar rates to patients with ACS (4). In the Takotsubo registry, 20% of patients met a composite endpoint of requiring catecholamines for hemodynamic support, cardiogenic shock, resuscitation (e.g., mechanical ventilation, intra-aortic balloon pump), and death. While the overall course is fairly benign for most patients, a sizable portion can suffer very serious, life-threatening outcomes.

The patient we present in this case fortunately had a favorable outcome. She did not require mechanical ventilation or hemodynamic support. She was discharged from the hospital after a short stay and did not report any new symptoms of chest pain or dyspnea on exertion. She was given a prescription for a beta-blocker and an angiotensin-converting enzyme-inhibitor and follow-up was arranged with a cardiologist in 3 weeks.

Repeat TTE done prior to this follow-up visit revealed a low-normal left ventricular ejection fraction (55%) as well as normalized ventricular wall motion.

Unfortunately, the patient continued to experience neck pain with inadequate relief from the RFA. This poses a difficult decision for both the patient and her physician: if she suffered a reaction this severe to one RFA, is it possible (or even likely) to have a similar response to repeat procedures? In the Takotsubo registry, the recurrence rate was reported at 1.8% per patient-year. Another study of 130 patients reported a 5% recurrence rate over the mean 2.3-year follow-up period, with 5 of those 7 patients being triggered by similar events (8).

CONCLUSIONS

This case is an interesting example of the unique adverse events and clinical decision points that we encounter in medicine. While the recurrence rate of this particular syndrome is considered fairly low, a frank conversation with the patient regarding risks of another procedure is certainly warranted. When considering future treatment options, alternative options for pain management other than RFA may be more prudent than potentially exposing the patient to another possibly unsuccessful procedure that poses a relatively increased risk for developing another case of Takotsubo cardiomyopathy.

REFERENCES

1. Kornick C, Scott KS, Lamer TJ, Todd SB. Complications of lumbar facet radiofrequency denervation. *Spine* 2004; 29:1352-1354.
2. Sato H, Tateishi H, Uchida T, et al. Takotsubo type cardiomyopathy due to multivessel spasm. In: Kodama K, Haze K, Hon M, eds. *Clinical Aspect of Myocardial Injury: From Ischemia to Heart Failure*. Tokyo, Kagaku Hyoronsha, 1990: pp. 56-64.
3. Lakdawala NK, Stevenson LW, Loscalzo J. Cardiomyopathy and myocarditis. In: Jameson J, Fauci AS, Kasper DL, Hauser SL, Longo DL, Loscalzo J (eds). *Harrison's Principles of Internal Medicine*. 20th ed. New York, McGraw-Hill, 2018. Accessed May 25, 2021. <https://accessmedicine.mhmedical.com/content.aspx?bookid=2129§ionid=192029156>.
4. Templin C, Ghadri JR, Diekmann J, et al. Clinical features and outcomes of Takotsubo (stress) cardiomyopathy. *N Engl J Med* 2015; 373:929-938.
5. Joo I, Lee JM, Han JK, Choi BI, Park EA. Stress (Tako-Tsubo) cardiomyopathy following radiofrequency ablation of a liver tumor: A case report. *Cardiovasc Intervent Radiol* 2011; 34:86-89.
6. Hasdemir C, Yavuzgil O, Simsek E, Ulucan C, Cinar CS. Stress cardiomyopathy (Tako-Tsubo) following radiofrequency ablation in the right ventricular outflow tract. *Europace* 2008; 10:1452-1454.
7. Rodwell VW. Biosynthesis of the nutritionally nonessential amino acids. In: Rodwell VW, Bender DA, Botham KM, Kennelly PJ, Weil P (eds). *Harper's Illustrated Biochemistry*. 31st ed. New York, McGraw-Hill, 2018. Accessed May 25, 2021. <https://accessmedicine.mhmedical.com/content.aspx?bookid=2386§ionid=187832918>.
8. Sharkey SW, Windenburg DC, Lesser JR, et al. Natural history and expansive clinical profile of stress (Tako-Tsubo) cardiomyopathy. *Am J Cardiol* 2010; 55:333-341.

