

# **MEDIAL AND LATERAL BURNS WITH CONCOMITANT INFECTION AFTER GENICULAR NERVE RADIOFREQUENCY ABLATION: A CASE REPORT**

Mark P. Pressler, MD<sup>1</sup>, Priyanka Singla, MD<sup>1,2</sup>, Yasmin Sritapan, DO<sup>1,2</sup>, Lynn R Kohan, MD<sup>1,2</sup>, and Bhavana Yalamuru, MBBS<sup>1,2</sup>

**Background:** Knee osteoarthritis management might include medication, intraarticular injections, physical therapy, and surgical intervention. Genicular nerve radiofrequency ablation (RFA) is an effective therapy for patients who do not receive benefit from conservative medical management and are not surgical candidates (secondary to medical comorbidity, patient preference, and other factors). Genicular nerve RFA is generally safe and has a low complication rate. However, there have been case reports of minor and major complications after RFA. We report a case of burns after genicular nerve RFA.

**Case Report:** A 49-year-old man (92 kg; body mass index [kg/m<sup>2</sup>] 28.3), with a history of coronary artery disease and chronic tobacco use, presented with 20 years of chronic knee pain. He previously had short-term relief with an intraarticular steroid knee injection. He was found to be a suitable candidate for genicular nerve RFA and underwent the procedure successfully without any immediate complications. His pain decreased from 9/10 before the procedure to 5/10 after his RFA. On postprocedure day 33, a 1 cm circular lesion with drainage was noted on the medial aspect of his knee. A lateral lesion was discovered at a subsequent follow-up appointment. He was treated with antibiotics, chlorhexidine cleansing, and dressing changes which resolved the lesions without any long-term sequelae.

**Conclusion:** Our case represents an instance of full thickness skin burns with concomitant infection post genicular RFA, uniquely in both the medial and lateral sites. Our patient's risk factors of low body mass index, smoking, and vascular disease may have led to a delayed healing response. In addition, needle depth may also have contributed to his injury. Ensuring adequate needle depth and patient selection can minimize these complications.

**Key words:** Radiofrequency ablation, knee pain, osteoarthritis, chronic pain, genicular nerve, RFA, adverse event, complication

## **BACKGROUND**

Knee osteoarthritis (OA) is a common source of pain and disability (1). Traditional management of OA might include pharmacotherapy, physical therapy, intraarticular injections, and surgical intervention (2). Genicular nerve radiofrequency ablation (RFA) is commonly performed on patients who are not surgical candidates,

secondary to medical comorbidity, patient preference, and other factors (1-6). In addition, those with persistent postoperative total knee replacement pain are good candidates for genicular RFA (1,2,6). Previous literature has documented minor complications from RFA (1,2), as well as more serious adverse events such as 3rd degree burns (3,5), hematoma (2,5,7), and septic arthritis (2,8).

From: <sup>1</sup>University of Virginia Department of Anesthesiology, Charlottesville, VA; <sup>2</sup>UVA Pain Management Center, Charlottesville, VA

Corresponding Author: Bhavana Yalamuru, MBBS, E-mail:BY2G@uvahealth.org

Disclaimer: There was no external funding in the preparation of this manuscript.

Conflict of interest: Each author certifies that he or she, or a member of his or her immediate family, has no commercial association (i.e., consultancies, stock ownership, equity interest, patent/licensing arrangements, etc.) that might pose a conflict of interest in connection with the submitted manuscript.

Patient consent for publication: Consent obtained directly from patient(s).

This case report adheres to CARE Guidelines and the CARE Checklist has been provided to the journal editor.

Accepted: 2024-01-05, Published: 2024-04-30

This case report documents burns/poor wound healing post genicular RFA on a patient with moderate OA.

### CASE PRESENTATION

A 49-year-old man (92 kg; body mass index [kg/m<sup>2</sup>] 28.3) with a history of coronary artery disease (with previous myocardial infarction) and chronic tobacco use presented to our institution's pain management center reporting 20 years of chronic right knee pain. He had failed conservative therapy as well as an intra-articular steroid injection. He was found to be a suitable candidate for genicular nerve RFA and was enrolled in a study protocol for the same. He underwent a right genicular nerve ablation using the Stryker Venom RFA needle system (Stryker Instruments) on 9 nerve targets as per study protocol (Fig. 1 [9]). Eighteen gauge, 100 mm needles were placed at the target nerves which was followed by uneventful sensory/motor nerve testing. After local anesthetic injection, RFA was performed at each site for 150 seconds at 80°C (Fig. 2a – 2f). During the first post-RFA week, he noted about 50% pain relief.

At his follow-up appointment on postprocedure day

(PPD) 33, a 1 cm circular lesion with drainage was noted on the medial aspect of his knee. He reported that the area around his medial knee had become red and swollen shortly after the procedure, but he was unable to recall any further details. He self-administered triple antibiotic ointment and hydrogen peroxide to cleanse the wound. An x-ray obtained at that follow-up visit showed no evidence of bony involvement or osteomyelitis. He was started on a course of trimethoprim/sulfamethoxazole prophylactically after consulting with our plastic surgery colleagues.

On PPD 40, a 1 cm lesion was noted at a lateral injection site that began to have some drainage (Fig. 3a and 3b). A second week of antibiotics were prescribed, as well as wet-to-dry dressing changes with chlorhexidine cleansing. On PPD 49, we noted improvement in both medial (Fig. 3c) and lateral (Fig. 3d) wounds with minimal drainage. A third week of antibiotics were prescribed.

He had a total 21-day course of trimethoprim/sulfamethoxazole. On PPD 54 the patient's wounds (Figs. 3e and 3f) continued to improve, and granulation tissue

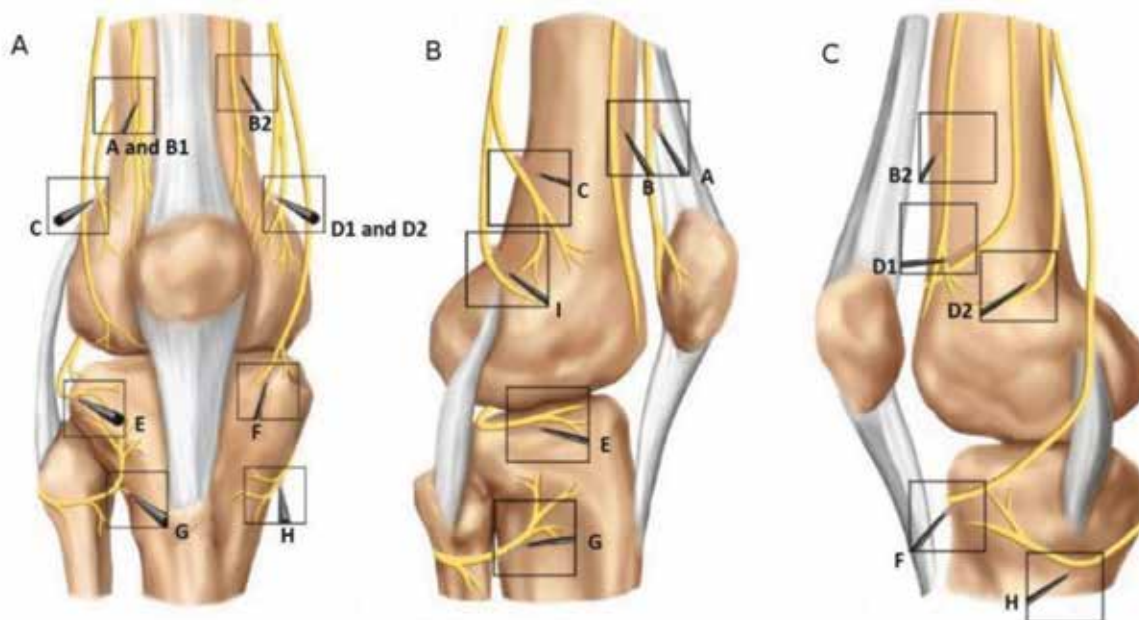


Fig. 1. McCormick, et al (10) documented a way to approach genicular nerve radiofrequency ablation, utilized for the patient in this report. Innervation of the knee joint is shown in 3 views: (A) anterior, (B) lateral, (C) medial. The following nerves were targeted for the patient in this report: A) nerve to vastus lateralis; B1) lateral branch of the nerve to vastus intermedius; B2) medial Bbranch of the nerve to vastus intermedius; C) superior lateral genicular nerve; D1) nerve to vastus medialis; D2) superior medial genicular nerve; E) interior lateral genicular nerve; F) infrapatellar branch of the saphenous nerve; H) interior medial genicular nerve. For the patient in this report, (G) recurrent fibular nerve, was not targeted (10). Used with permission from McCormick, et al.

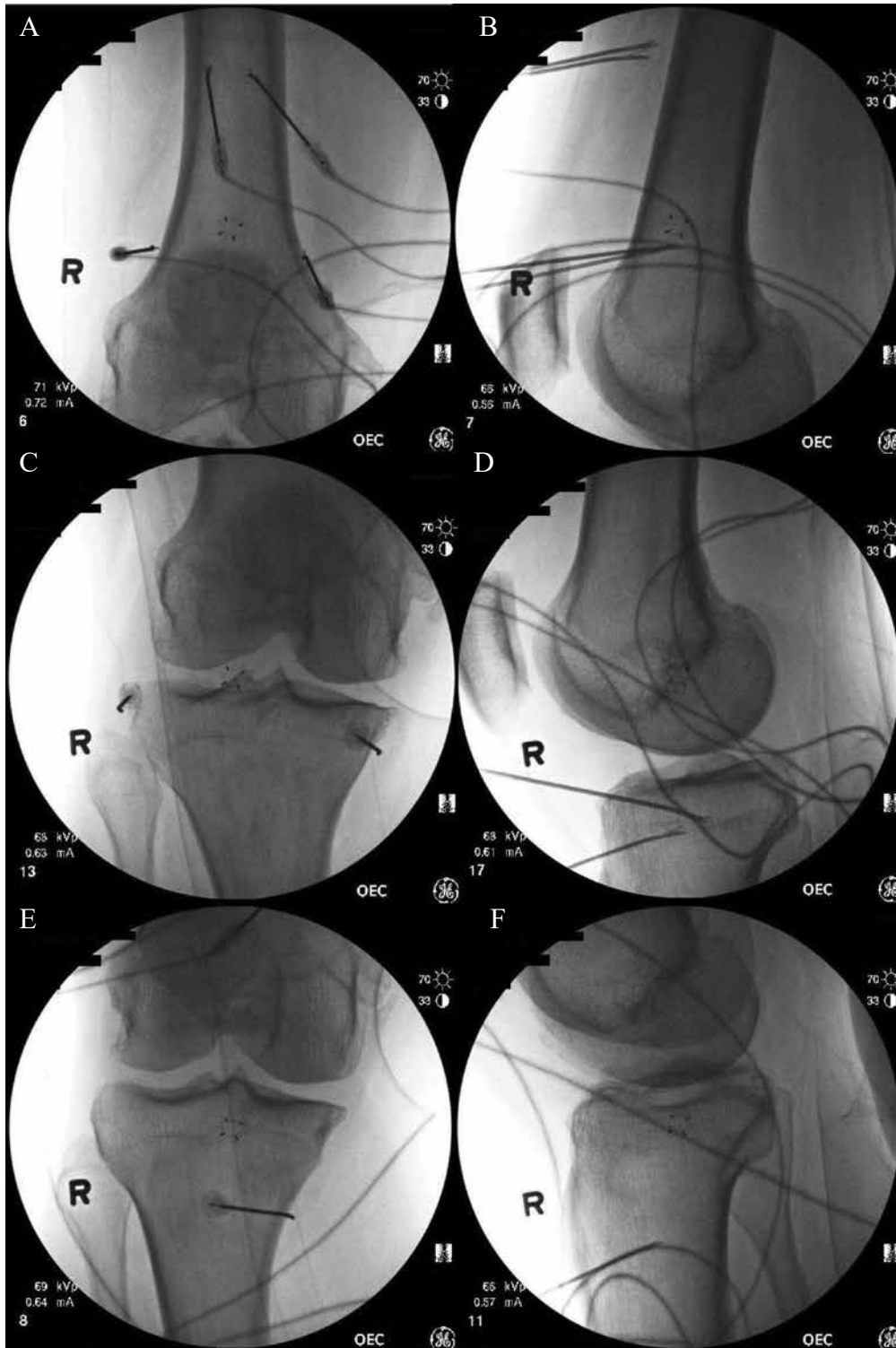


Fig. 2. A) Represents the fluoroscopy image where the radiofrequency (RF) needle targets A, B1, B2, C, D1, and D2 in Fig. 1; B) Represents the lateral view of targets A, B1, B2, C, D1, and D2; C) Represents the RF needle targeting E and F in Fig. 1; D) Shows the lateral view of targets E and F; E) Represents the RF needle targeting H in Fig. 1; F) Shows the lateral view of target H. These images are provided because previous case reports (3,5) discussed the habitus of their patients and postulated that superficial RF needle placement contributed to their patients' burn.

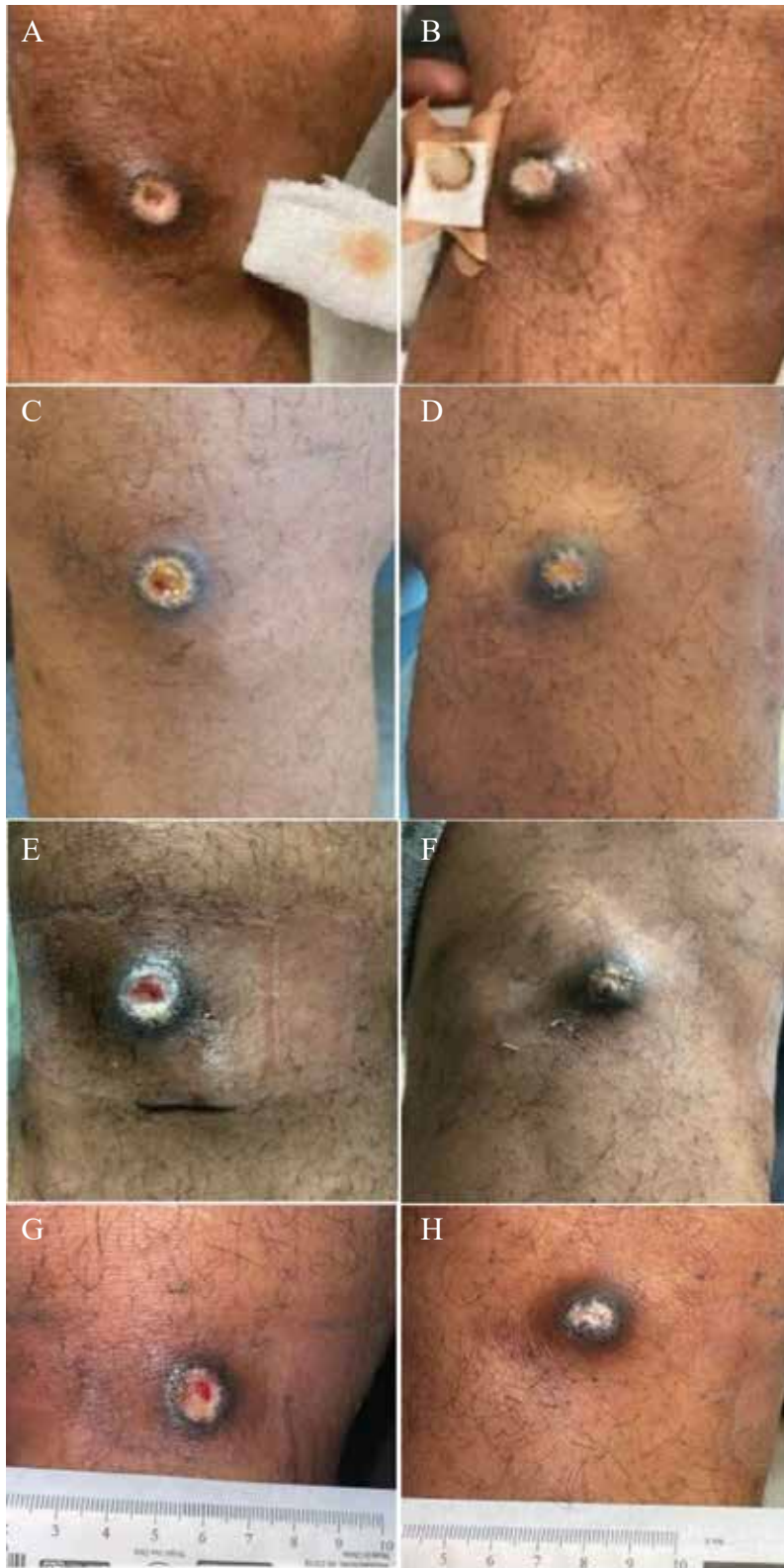


Fig. 3. A) shows the patient's medial wound on postprocedure day (PPD) 33; B) shows the lateral wound on PPD 33; C) shows the medial wound on PPD 40; D) shows the lateral wound on PPD 40; E) shows the medial wound on PPD 54; F) shows the lateral wound on PPD 54; G) shows the medial wound on PPD 61; H) shows the lateral wound on PPD 61; This figure shows the healing course despite a 21 day course of trimethoprim/sulfamethoxazole as well as wet-to-dry dressing changes with chlorhexidine. Of note, the ruler appearing in the bottom row of Fig. 3 is not scaled to the other images.

formation was noted. On PPD 61 (Fig. 3g and 3h) we noted continued wound healing. At his most recent follow-up, we noted complete healing.

## DISCUSSION

Genicular RFA is an option for patients who have pain refractory to conservative or surgical management (1,2,6). Conger, et al (1) and Cheppalli, et al (2) report low post-RFA complication rates. The majority of complications are minor; they include numbness, bruising, pruritus, and erythema (1,2,10,11).

However, a few case reports detail more serious adverse events related to RFA: third degree burns (6,12), grounding pad burns (13,14), hematoma (2,5,7), neuropathy (12), and septic arthritis (2,8). One case of a genicular RFA burn (3) healed with conservative management. Another (5) required hydrocolloid dressing changes for healing. The RFA for a thyroid lesion (12) required surgical debridement, topical antibiotics, hyaluronic acid, silver, and later, collagen dressings. The reported time to heal varied from 3 weeks to 5 months, suggesting a wide variation (3,5,12). Smoking and vascular disease have been identified as risk factors for delayed wound healing (15).

The patient in our case was an active smoker with a history of vascular disease and prior myocardial infarction. Thus, he probably had a delayed healing response given his multiple wounds. This delayed course required antibiotics, wet to dry dressing changes, and chlorhexidine rinses.

In this case, our patient noted redness and swelling soon after his procedure, which corresponds with the full thickness burn timeline described by other authors (3,6,12-14). McCormick, et al (3) and Walega, et al (5), in their case reports of burns after radiofrequency ablations, noted symptoms of skin changes either during the procedure or in the postprocedure care unit. In addition,

both case reports noted their patients were slender and postulated the superficial placement of the RFA needle (because of minimal overlying subcutaneous tissue) as a possible factor contributing to burns (3,5). Thus, they recommended selecting an individualized RFA electrode size and length (3,5).

The fluoroscopy images in our case suggest adequate needle depths (Fig. 2a – 2f). McCormick and Walega (3) reported no discomfort during their procedure. During the procedure, the proceduralist noted a 7-8 mm erythematous area without skin breakdown. The lesion was noticed at the 5-week follow-up; the patient reported no pain at the appointment and an effective RFA (3). Walega and Roussis (5) noted skin blanching during their RFA procedure and immediate, localized, nonradiating pain. The RFA was aborted after 90 seconds of burning. All other RFA burns during the procedure were uneventful (5). Bernardi, et al (12), who reported a case involving a burn during RFA for the thyroid gland (12), noted that the proceduralist saw a skin burn but the patient did not express any symptoms/pain. The patient in Bernardi's case did not report pain out of proportion compared to other patients undergoing the same procedure.

## CONCLUSION

Our case report describes full thickness skin burns with concomitant infection post genicular RFA, uniquely at both medial and lateral sites. Our patient's risk factors of smoking and vascular disease may have led to a delayed healing response (16). In addition, it is possible that the needle, while not appearing superficial on fluoroscopy (Fig. 2a – 2f), disrupted the delicate dermal/subcutaneous vascular plexus and led to the patient's wounds. Therefore, we recommend caution in patients with a low body mass index in order to ensure adequate depth and appropriate electrode choice prior to RFA to minimize the risk of such complications.

## REFERENCES

1. Conger A, Gililand J, Anderson L, Pelt CE, Peters C, McCormick ZL. Genicular nerve radiofrequency ablation for the treatment of painful knee osteoarthritis: Current evidence and future directions. *Pain Med* 2021; 22:S20-S23.
2. Cheppalli N, Bhandarkar AW, Sambandham S, Oloyede SF. Safety and efficacy of genicular nerve radiofrequency ablation for management of painful total knee replacement: A systematic review. *Cureus* 2021; 13:e19489.
3. McCormick ZL, Walega DR. Third-degree skin burn from conventional radiofrequency ablation of the inferiomedial genicular nerve. *Pain Med* 2018; 19:1095-1097.
4. Koshi E, Cheney CW, Sperry BP, Conger A, McCormick ZL. Genicular nerve radiofrequency ablation for chronic knee pain using a three-tined electrode: A technical description and case series. *Pain Med* 2020; 21:3344-3349.
5. Walega D, Roussis C. Third-degree burn from cooled radiofrequency ablation of medial branch nerves for treatment of thoracic facet syndrome. *Pain Pract* 2014; 14:e154-e158.

6. Choi WJ, Hwang SJ, Song JG, et al. Radiofrequency treatment relieves chronic knee osteoarthritis pain: A double-blind randomized controlled trial. *Pain* 2011; 152:481-487.
8. Strand N, Jorge P, Freeman J, D'Souza RS. A rare complication of knee hematoma after genicular nerve radiofrequency ablation. *Pain Rep* 2019; 4:e736.
9. Khan D, Nagpal G, Conger A, McCormick ZL, Walega DR. Clinically significant hematoma as a complication of cooled radiofrequency ablation of the genicular nerves; A case series. *Pain Med* 2020; 21:1513-1515.
10. Khanna A, Knox N, Sekhri N. Septic Arthritis following radiofrequency ablation of the genicular nerves. *Pain Med* 2019; 20:1454-1456.
11. McCormick ZL, Cohen SP, Walega DR, Kohan L. Technical considerations for genicular nerve radiofrequency ablation: Optimizing outcomes. *Reg Anesth Pain Med* 2021; 46:518-523.
12. Iannaccone F, Dixon S, Kaufman A. A review of long-term pain relief after genicular nerve radiofrequency ablation in chronic knee osteoarthritis. *Pain Physician* 2017; 20:E437-E444.
13. Shields LBE, Iyer VG, Zhang YP, Shields CB. Iatrogenic neurological injury after radiofrequency ablation and epidural steroid injections: Illustrative cases. *J Neurosurg Case Lessons* 2021; 1:CASE2148.
14. Bernardi S, Lanzilotti V, Papa G, et al. Full-thickness skin burn caused by radiofrequency ablation of a benign thyroid nodule. *Thyroid* 2016; 26:183-184.
15. Goette A, Reek S, Klein HU, Geller JC. Case report: Severe skin burn at the site of the indifferent electrode after radiofrequency catheter ablation of typical atrial flutter. *J Interv Card Electrophysiol* 2001; 5:337-340.
16. Ibrahim H, Finta B, Rind J. Incidence and factors predicting skin burns at the site of indifferent electrode during radiofrequency catheter ablation of cardiac arrhythmias. *Cardiol Res Pract* 2016; 2016:5265682.
17. Ozgok Kangal MK, Regan JP. Wound Healing. [Updated 2022 May 8]. In: *StatPearls [Internet]*. Treasure Island, FL: StatPearls Publishing; 2022. [www.ncbi.nlm.nih.gov/books/NBK535406/?report=classic](http://www.ncbi.nlm.nih.gov/books/NBK535406/?report=classic)